International Journal of Law, Justice & Statutory Affairs
Volume 2, Issue 1, 2026

Clinical Case Report on Endoperiodontal Lesion

Irwansyah[1] , Eko Soponyono[2] , Ramon Nofrial[3]
Principal, A C College of Law,
Dean Faculty of Law, Acharya Nagarjuna University, Nagarjuna Nagar,

Research Article

Date of Submission: 15-01-2026 **Date of Acceptance: 26-02-2026** **Date of Publication: 19-003-2026**

Abstract

Background: Lesions when inflammatory materials are present in both the pulp and the periodontium are referred to as endoperiodontal lesions or endo-perio. Numerous classifications of endo-periodontal lesion alterations have been recorded as a result of the endodontic and periodontal relationship; for many years, the most widely used classification was based on the etiological sequence of the illness. By addressing the issue of utilizing the "history of the disease" as the primary criteria, the current "Classification of Periodontal and Peri-implant Diseases and Conditions (2017)" stands out for representing the current clinical situation of the lesion.

Objective:to assess how well an endoperiodontal lesion heals after periodontal therapy before receiving endodontic treatment.

Case report: Initially, supragingival and subgingival basic non-surgical periodontal treatment was used to treat an endoperiodontal lesion in a lower molar. Following that, three intracanal medication treatments and root canal obturation were part of the endodontic therapy.

Results: Regression of periodontal probing depth, tooth mobility, and radiographic bone healing of the endoperiodontal lesion could all be seen.

Conclusion: Since the goal of therapy is to address the two causes of harm, there was clinical success when periodontal treatment was carried out before endodontic treatment.

Keywords: Regenerative endodontics, periodontitis, and periapical periodontitis

Introduction

Lesions with inflammatory products present in both the periodontium and the pulp are referred to as endoperiodontal lesions or endo-perio. Simring and Goldberg were the first to describe the connection between pulpal and periodontal disorders [1].

Apical foramina, dentinal tubules, apical foramen, lateral, auxiliary, and secondary canals are the anatomical connections between periodontal and pulpal structures. Because its microbiota is diverse and mixed, with a preponderance of strict aerobes, these communication channels are responsible for the spread of pathological processes from one structure to another, which raises the possibility that a pulpal disease may have its periodontal origin as well as occur inversely. Endo-periodontal lesions may be caused by a variety of reasons, including trauma, root resorption, dental abnormalities, and perforations, in addition to the interaction of microorganisms [1].

Numerous categories of endoperiodontal changes have been identified as a result of the interaction between root canals and the periodontium. For many years, the most popular method was based on the disease's etiological sequence. Lesions were categorized as primary endodontic lesions, primary periodontal lesions, primary endodontic lesions with secondary periodontal involvement, primary periodontal lesions with secondary endodontic involvement, and genuine

endoperiodontal lesions based on this idea [2]. Although this categorization was extensively used, many of the clinical features of each category overlap with periodontal and endodontic diseases, making differential diagnosis challenging and, as a result, treatment and prognosis challenging [2]. True endo-periodontal lesion had the lowest percentage of right responses (35%) in a research aimed at assessing endodontists' expertise, followed by primary endodontic lesion with secondary periodontal involvement (40%) and primary endodontic lesion (68%) [3].

Endoperiodontal lesions are defined by the current Classification of Periodontal and Peri-implant Diseases and Conditions (Chicago Classification, 2017) [4] as an acute or chronic pathological communication between pulpal and periodontal tissues in a particular tooth. Deep periodontal pockets that reach the root apex and/or a negative or altered pulp vitality test result are characteristics of this disorder. Evidence of radiographic bone loss in the apical or furcation area, discomfort that occurs spontaneously or with palpation or percussion, purulent discharge or suppuration, tooth movement, fistula, and color changes in the tooth crown and/or gingiva are other potential signs and symptoms. Endoperiodontal lesions are now divided into three categories: endoperiodontal lesions in patients with periodontitis, endoperiodontal lesions in patients without periodontitis, and endoperiodontal lesions with root damage (perforation of the root canal or pulp floor, root fracture, and external root resorption). Grades 1, 2, and 3 can still be used to classify lesions in patients with or without periodontitis. A narrow and deep periodontal pocket on a root surface is equivalent to grade 1, a wide and deep periodontal pocket on a root surface is equivalent to grade 2, and the presence of deep periodontal pockets on two or more root surfaces is equivalent to grade 3.

Accordingly, anamnesis and comprehensive clinical

Exams are essential for the right diagnosis. The kind and extent of the periodontal lesion, as well as pulp vitality, are the primary variables to be monitored [5]. In order to verify the integrity of periodontal and periapical tissues and their long-term preservation, radiographic tests are crucial as a supplement to clinical evaluations. The right diagnosis is crucial for identifying the disease's etiological elements, as well as for selecting the best treatment technique and course of action to eradicate the bone defect it causes. Studies are required to assess various options for treating endoperiodontal lesions, as well as the suitability of the categorization of endoperiodontal lesions in light of the condition's present status.

This article's goal is to assess how well periodontal therapy heals an endoperiodontal lesion before endodontic therapy. It is hypothesized that the healing of endoperiodontal lesions may not depend on the prescribed course of therapy.

Case Presentation

The Centro Universitación do Distrito Federal UDF's Research Ethics Committee authorized the clinical case under CAAE 18070319.3.0000.5650.

A 25-year-old female patient sought dental treatment at the University Center of Federal District (UDF) dental clinic, reporting that she had been experiencing lower left tooth ache for a while. The patient denied systemic changes, medication allergies, and poor oral hygiene during the anamnesis. The clinical examination confirmed this, showing an O'Leary stained plaque index (1972) [6] of 84.2% with a plaque (Eviplac®, Ibiporá, Paraná, Brazil) and generalized gingivitis (bleeding on probing above 30%) [4]. According to the Classification of Periodontal and Peri-implant Diseases and Conditions, a buccal fistula was found in tooth 36 along with an amalgam restoration on the occlusal surface (Black Class I) and a negative reaction to the thermal test with refrigerated gas (ENDO-ice®, Maringá, Paraná, Brazil). A periodontal examination revealed mobility grade [2], when the crown of the tooth moves up to one millimeter in any direction [7–10]. A large radiolucent region including tooth 36's mesial and distal roots was seen during the radiography examination (Figure 1). A patient with periodontitis and grade 3-deep periodontal pockets on two or more root surfaces (probing depth of 5 mm at the mesio-buccal and distobuccal sites) was found to have an endoperiodontal lesion based on the clinical and radiological findings [4].

In light of the diagnosis, the clinical case planning process began with supragingival scaling using ultrasonography (Dabi), modifying the oral environment with prophylaxis and personalized oral hygiene recommendations.

Table 1: Periogram tooth 36.

	MB	B	DB	ML	L	DL

Probing Depth	5	4	5	5	4	4
Clinical Attachment Loss	7	5	6	7	5	5
Bleeding on Probing	yes	yes	yes	yes	yes	yes
Furca Lesion	-	II	-	-	II	-
Mobility	2					

MB: Mesiobuccal, B: Buccal; DB: Distobuccal; ML: Mesiolingual; L: Lingual; DL: Distolingua



Figure 3: (A). X-ray demonstrating the regression of the lesion on tooth 36 before root canal filling (120 days). (B). after completion of endodontic treatment (120 days).



Figure 1: Initial radiograph of tooth 36 with extensive radiolucent area involving the roots.

Gracey curettes (Golgran®, São Caetano do South, São Paulo, Brazil) and Atlante®, Londrina, PR, Brazil. Following gingivitis treatment, subgingival scaling was carried out using Gracey curettes under local anesthetic, Mepivacaine HCI 2% with epinephrine 1:100,000 (DFL®, RJ, Brazil).

Tooth 36's endodontic treatment began fourteen days after subgingival scaling was finished. The coronal orifice was drained of purulent exudate. Following odontometry (distobuccal canals: 23 mm, mesiobuccal canals: 21 mm, distolingual canals: 21 mm, and mesiolingual canals: 21 mm), chemical-mechanical preparation was carried out using irrigation with 2.5% hypochlorite (Asfer®, São Caetano do Sul, SP, Brazil) and instrumentation with a Protaper rotary system (Dentisply®, Pet Españpolis, RJ, Brazil) up to F2 in all conduits. A paste made of PA calcium hydroxide (Biodinam®, Ibiporá, PR, Brazil), propylene glycol (Medalha Milagrosa compounding pharmacy, Cristalina, GO, Brazil), and iodoform (Biodinam®, Ibiporá, PR, Brazil) (Figure 2A) was administered intracanally using lentulo files (Dentisply®, Pet Españpolis-RJ, Brazil). Next, zinc oxide and eugenol (IRM®, Dentisply, Petrópolis, RJ, and Brazil) were used to temporarily close the cavity. Propylene glycol, iodoform, and PA calcium hydroxide paste were used to replace the medicine after 14 and 21 days, and zinc oxide and eugenol were used to temporarily close the cavity (Figure 2B).

The patient returned after 4 months with no fistula and no symptoms. Tooth mobility went from grade 2 to grade 1, and considerable regression of the lesion was observed on radiography (Figure 3A). The root canals were filled with gutta-percha F2 by Protaper (Dentisply®, Petrópolis, RJ, Brazil) and MTA Fillapex cement (Angelus®, Londrina, PR, Brazil), in addition to provisional restoration with glass ionomer (FGM®, Joenville, SC, Brazil) (Figure 3B).

The follow-up consultation at 6 months showed no fistula and any symptoms, reduced mobility to grade 1, reduced probing depth from 5 mm and 4 mm to 2 mm, and radiographically observed bone gain.

Discussion

The current clinical case shows how periodontal therapy and a root canal may effectively cure an endo-perio genesis lesion. To accomplish the disinfection and restoration of the whole system concerned, one scope works in tandem with the other.

The existence of fractures, perforations, and periodontitis are examples of signs and symptoms that must be taken into consideration when classifying endoperiodontal diseases since they have a direct impact on their prognosis and course of therapy. Although these lesions are uncommon in clinical practice, they nonetheless provide a significant knowledge challenge for dental surgeons. They fall into a category that warrants discussion since they have an impact on the tooth's prognosis. As a result, this clinical condition is regarded as one of the biggest obstacles in the clinical routine because it needs careful attention from diagnosis to treatment, as the effectiveness of the therapy depends on the accurate

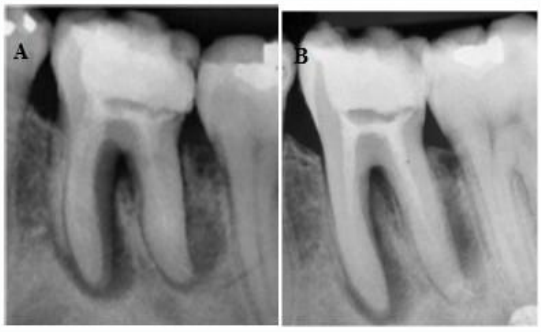

Figure 2: (A). Radiograph of tooth 36 after intracanal medication (14 days). (B). Change of intracanal medication (21 days).

diagnosis linked to the appropriate treatment [10].

It is difficult to diagnose these endodontic and periodontal diseases in this situation, but doing so is essential to developing a suitable course of therapy. Pulp vitality tests, periodontal exams, probing depth, and periodontal pocket expansion, which may be related to the percussion test, may distinguish a lesion that is exclusively of endodontic or periodontal origin [11]. Deep periodontal pockets that reach the root apex and/or a negative or altered response to pulp vitality tests are the main indicators of this lesion. Radiographic evidence of bone loss in the apical or furcation area, discomfort that occurs on its own or in response to probing or percussion, purulent discharge or suppuration, tooth movement, sinus tract or fistula, and color changes in the crown and/or gingiva are additional indications and symptoms. To provide a favorable prognosis for therapy, it is essential to choose the appropriate diagnostic tests and to correctly interpret the findings [12].

An endodontic lesion may heal more successfully when endodontic and periodontal treatment are combined [13,14]. This is due to the possibility of an inflammatory resorption caused by bacteria in the root canal, which exposes periodontal tissues and exposes them to harmful drugs used in the canal. In endo-perio therapy, early endodontic treatment preserves the cementum layer, which lowers the likelihood of potential root resorption. In an acute condition, the system generating the pain or edema must be addressed first; that is, the main illness must be treated before treating the secondary lesion. When a mixed lesion is diagnosed, concurrent therapy is also an option [11].

Calcium hydroxide was the preferred therapy in this research because it may activate tissue enzymes like alkaline phosphatase, which promote tissue regeneration via mineralization. This enzyme may be activated at pH values between 8.6 and 10.3. This allows for the release of organic phosphate (phosphate ions), which combine with circulating calcium ions to form a calcium phosphate deposit in the organic matrix 11. The high pH of calcium hydroxide in this region, which may reach 12.6 due to the release of hydroxyl ions, might change the integrity of the bacterial cytoplasmic membrane and provide the antibiotic action linked to mineralization. In endodontic infections, time must be given for the calcium hydroxide paste to fulfilll its action potential [11,15]. According to Guimaraes et al. [16], it is best to apply the calcium hydroxide delay dressing to teeth that have pulp necrosis after at least 15 days, as was done in our investigation.

Supragingival and subgingival covering are necessary for periodontal therapy. Restoring health and periodontal reconstruction are the goals of periodontal therapy, which may include bone grafting and papillary esthetic repair as tools [17].

Conclusion

Since treating the two causes of an endoperiodontal lesion is the main need for therapy, it is possible to infer from the treatment and follow-up of the current case that there is clinical success when periodontal treatment is carried out prior to endodontic treatment.

References

1. The pulpal pocket approach: retrograde periodontitis, Simring M, Goldberg M. J Period. 1964; 35:22–48.

2. Santos ACB, Lins CCdSA. Endodontists' decision-making in the diagnosis and management of endoperiodic lesions in the city of Maceção-2007. Int J Dent. 6(3):80-5, 2008.

3. Pereira TT, Bordin GM, and Sorrer CM. How are periodontal-endodontic lesions diagnosed and treated? RSBO. 9(4):427-33, 2012.

4. Marcantonio RAC, Steffens JP. The 2018 Classification of Periodontal and Peri-implant Diseases and Conditions: A Useful Guide and Essential Elements. Rev. Odontol UNESP. 47(4):189-97, 2018.

5.Dahlen G. Microbiology and management of periodontal-endodontic diseases and tooth abscesses. Periodontol 2000. 28:206-39, 2002.

6. The plate control record, O'Leary TJ, Drake RB, Naylor JE. J Periodontol. 43(1):38, 1972.

7. Hutchinson CA Jr., Miller CC, and Dyes AB. Permeability and reservoir pressure are estimated using bottom hole pressure build-up characteristics. J Pet Technol. 2(04):91-104, 1950.

Microbiomes of endodontic-periodontal lesions before to and during chemomechanical preparation (Gomes BPFA, Berber VB, Kokaras AS, Chen T, Paster BJ). J. Endod. 41(12):1975-84 (2015).

9. Xia M, Qi Q. Polymerase chain reaction denaturing gradient gel electrophoresis for bacterial analysis of mixed periodontal-endodontic diseases. J. Oral Sci. 55(4):287-91 (2013).

10. Al Attas MA, Edrees HY, Sammani AMN, Madarati AA. A case report on the multidisciplinary treatment of concurrent periodontal and pulpal damage. J. Taibah

2017; 12(5):455-60; Univ Med Sci.
11. Estrela C, Holland R. Calcium hydroxide: a scientifically supported investigation. J Appl Oral Sci. 11(4):269-82, 2003.
12. Endoperiodontal lesion: A case report, Sartori S, Silvestri M, Cattaneo V. J Clin Periodontol. 29(8):781-3, 2002.
13. Holthuis AF, Christie WH. The diagnosis and prognosis of the endo-perio issue in dentistry. J. Can Dent Assoc. 56(11):1005-11, 1990.
14. Current methods for diagnosing and treating endoperiodontal lesions de Lima Dantas LTB, Carvalho IF, Lima DVdSC, da Silva Ribeiro M, Martins G, and Cerqueira JDM. J. Dent Public Health. 10(2):135-146, 2019.
15. Holland R, Merida Delgado RJ, Souza Vd. Do tunnel-shaped flaws in dentin bridges only occur when calcium hydroxide is used? Rev. Ci."c. Odontol. 2001:51–56.
16. Guimaraes KB, Post LK, Isolan CP, Bezerra MF, Hosni ES. A case study of parendodontic surgery combined with concurrent root canal obturation. Rev. Biol. 2006; 5(2):188-94.
17. Papillary restoration and directed tissue regeneration for mixed periodontal-endodontic diseases produced by palatogingival groove and extra root: a case study Miao H, Chen M, Otgonbayar T, Zhang SS, Hou MH, Wu Z, et al. Clin Case Rep. 3(12):1042-9, 2015.